

Mohamed Osama Hegazi, Mohamed Mourou, Omar Ahmed Hassanien

## **Antiphospholipid Syndrome Presenting with Superior Vena Cava Thrombosis**

Article Type: CASE REPORT

The *Iranian Journal of Immunology* is a quarterly Peer-Reviewed Journal Published by Shiraz Institute for Cancer Research and the Iranian Society of Immunology & Allergy, Indexed by Several World Indexing Systems Including:  
Index Medicus and Pubmed

**For information on author guidelines and submission visit:**

**[www.iji.ir](http://www.iji.ir)**

**For assistance or queries, email:**

**[iji@sums.ac.ir](mailto:iji@sums.ac.ir)**

## **CASE REPORT**

# **Antiphospholipid Syndrome Presenting with Superior Vena Cava Thrombosis**

Mohamed Osama Hegazi<sup>1\*</sup>, Mohamed Mourou<sup>1</sup>, Omar Ahmed Hassanien<sup>2</sup>

<sup>1</sup>Department of Medicine, Al Adan Hospital, <sup>2</sup>Department of Radiology, Yaco-Al Adan center, Kuwait

## **INTRODUCTION**

Blood flow obstruction in the superior vena cava (SVC) results in symptoms and signs of SVC syndrome. SVC obstruction is caused either by invasion or external compression of the SVC by contiguous pathologic processes involving the right lung, lymph nodes, and other mediastinal structures, or by thrombosis within the SVC. In the past, syphilitic aortic aneurysms and infections were frequent causes, but nowadays, malignancy represents the most common etiology (1-3). SVC thrombosis accounts for a significant proportion of the remaining non-malignant causes of SVC obstruction (2). Many of these are related to the presence of indwelling central venous devices, including pacemaker/defibrillator leads or hemodialysis catheters (2). We report a case of thrombosis of the SVC leading to SVC syndrome as a manifestation of the antiphospholipid syndrome (APS).

**Keywords: Antiphospholipid, Superior vena cava**

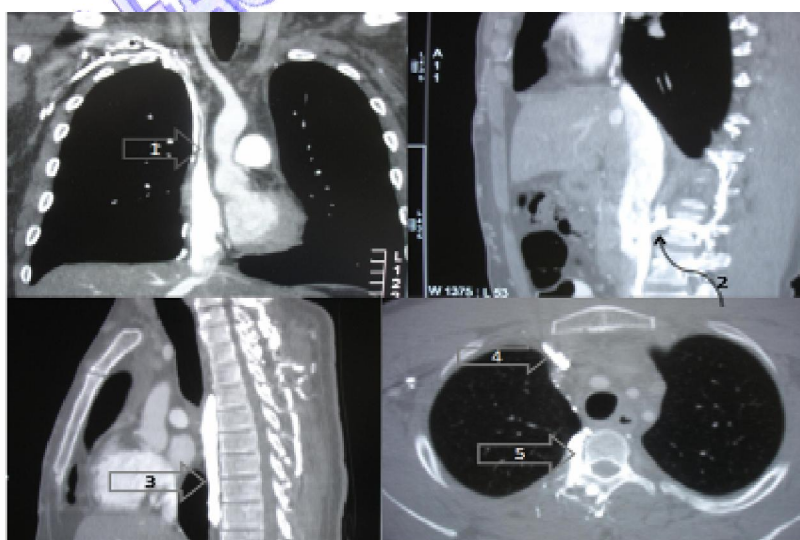
## **CASE REPORT**

A 30-year-old man presented with swelling of the face of 2 months duration. The history, otherwise, was unremarkable and especially was negative for fever, dyspnoea, weight loss, neck lumps, leg swelling, and orogenital ulcers. There was no history of pacemaker or central venous line implantation. Clinically, he had a swollen plethoric face, congested non-pulsating neck veins, and swollen arms, with dilated tortuous veins over upper arms and anterior chest wall. Liver and spleen were not palpable and he had no lymphadenopathy. Respiratory and cardiovascular examinations were unremarkable. Chest X ray, electrocardiogram, and echocardiogram were normal. Chest contrast-enhanced computed tomography (CT) showed no abnormal masses or lymph nodes. There was

---

\*Corresponding author: Dr. Mohamed Osama Hegazi, MRCP (UK), P. O. Box: 47813, Fahaheel, 64029, Kuwait, Tel: (+) 96 597403085 Fax: (+) 96 523941638, email: drosama02@gmail.com

marked narrowing of the SVC with a mural filling defect (mostly due to chronic thrombosis) and a clear evidence of collaterals leading to distension of internal mammary, anterior chest wall, azygous, and hemiazygous veins (Figure 1). Upper limb venography showed bilateral chronic complete occlusion of the brachiocephalic veins and the SVC with multiple cervical, mediastinal, and vertebral collateral channels which shunt the blood into the inferior vena cava via enlarged azygous and hemiazygous veins. Initial laboratory investigations including full blood count with hepatic and renal profiles were normal. Coagulation profile was normal with prothrombin time = 11 seconds, activated partial thromboplastin time = 34 seconds, and INR=1. D-dimer was raised with a value of 470  $\mu\text{g/L}$  (Normal reference range=0–300  $\mu\text{g/L}$ ). Tests for plasma fibrinogen, homocysteine, protein C, protein S, activated protein C resistance, and anti-thrombin-III were normal. Blood cultures, serology for antifilarial antibody, tuberculin test, and pathology test were negative. Rheumatoid factor and antinuclear antibody tests were negative as well. Venereal Disease Research Laboratory (VDRL) test was positive, but the fluorescent treponemal antibody absorption (FTA-ABS) test was negative. Anticardiolipin antibody and anti  $\beta$  2 glycoprotein 1 antibody were negative, but the lupus anticoagulant test was strongly positive with an initial value of 102 seconds (normal range=42-54 seconds), a confirmatory value of 48.60 seconds (normal range=29-37 seconds), and a ratio of 2.1. The lupus anticoagulant test remained positive with the same values when repeated 12 weeks thereafter. The exclusion of malignant and other non-malignant causes of SVC syndrome, occlusion of SVC associated with high D-dimer level, the repeatedly positive lupus anticoagulant tests, and absence of any stigmata of autoimmune or collagen disorders supported the diagnosis of SVC thrombosis due to primary APS. Intravascular stenting was not possible due to the long course of occlusion of the whole SVC and both brachiocephalic veins. The patient received long-term anticoagulation with warfarin at a target INR of 3-3.5. In spite of proper anticoagulation, there was only partial improvement in both face and arm swellings with no further episodes of arterial or venous thromboses over a one-year period of follow-up.



**Figure 1.** Images from chest CT with arrows pointing to markedly narrowed SVC (1), paravertebral veins communicating to inferior vena cava (2), dilated azygous vein (3), dilated right internal mammary vein (4), and dilated paravertebral veins (5).

## DISCUSSION

In the preantibiotic era, syphilitic thoracic aortic aneurysms, fibrosing mediastinitis, and other complications due to untreated infections were frequent causes of SVC syndrome (1). Nowadays, malignancy accounts for up to 78-90% of causes (2,3). Lung cancer is the most common malignant cause of the SVC syndrome, followed by lymphoma (3). Fibrosing mediastinitis accounts for about 50% of non-malignant causes and may be caused by excessive host response to infections including histoplasmosis, tuberculosis, actinomycosis, aspergillosis mucormycosis, blastomycosis, and cryptococcosis (4,5). Fibrosing mediastinitis manifests in chest X ray, chest CT or magnetic resonance (MR) images as a calcified or non-calcified mass or as infiltrates involving the mediastinum or the lung hilum with variable evidence of obstruction or compression of central airways, SVC, pulmonary veins, pulmonary arteries and esophagus (5). Other non-malignant causes of SVC syndrome are indwelling central venous devices, benign tumors of the mediastinum, mediastinal hematoma and sarcoidosis (2).

The APS is a thrombophilic disorder in which venous or arterial thrombosis, or both, may occur in patients with antiphospholipid antibodies (6). Based on a recent international consensus statement, the diagnosis of definite antiphospholipid syndrome must include at least one clinical event of arterial or venous thrombosis and at least one of two laboratory criteria [Lupus anticoagulant antibodies or anticardiolipin IgG or IgM antibodies present at moderate or high levels on two or more occasions at least six weeks apart] (7). Venous thromboses are more common than arterial thromboses in the APS and are reported to involve the deep veins of lower extremities (most common finding), the adrenal, hepatic, mesenteric, portal, or splenic vein, and the inferior vena cava (8). In a study by Provenzale et al., out of 93 patients with thrombotic events and positive antiphospholipid antibodies, 4(4.3%) had superior vena cava thrombosis (9). Alcazar-Ramirez et al. reported a case of extensive central vein thrombosis in the right internal jugular vein, superior vena cava, and both subclavian veins in a patient with APS (10). Ozkan et al. reported SVC thrombosis in a patient with malignant peritoneal mesothelioma and APS (11). Our case represents SVC syndrome as the sole manifestation of definite primary APS diagnosed according to the recent international criteria.

Endovascular wall stents have been successfully used in patients with benign SVC syndrome (12). SVC surgery with grafting (saphenous vein, femoral vein, or prosthetic grafts) or direct thrombectomy have been used for relief of the SVC syndrome (13). Long term anticoagulation with warfarin (international normalized ratio at or above 3) is indicated for patients with APS (6).

APS should be considered as one of the causes of SVC syndrome after exclusion of other more common etiologies especially lung cancer and lymphoma.

## ACKNOWLEDGEMENTS

No conflict of interest is declared

## REFERENCES

- 1 Schechter MM. The superior vena cava syndrome. *Am J Med Sci.* 1954; 227: 46-56.
- 2 Parish JM, Marschke RF Jr, Dines DE, Lee RE. Etiologic considerations in superior vena cava syndrome. *Mayo Clin Proc.*

## Antiphospholipid syndrom

- 1981; 56: 407-13.
- 3 Wilson LD, Deterbeck FC, Yahalom J. Clinical practice: Superior vena cava syndrome with malignant causes. *N Engl J Med.* 2007; 356: 1862-9.
  - 4 Schowengerdt CG, Suyemoto R, Main FB. Granulomatous and fibrous mediastinitis. A review and analysis of 180 cases. *J Thorac Cardiovasc Surg.* 1969; 57: 365-79.
  - 5 Rossi SE, McAdams HP, Rosado-de-Christenson ML, Franks TJ, Galvin JR. Fibrosing mediastinitis. *Radiographics.* 2001; 21: 737-57.
  - 6 Khamashta MA, Cuadrado MJ, Mujic F, Taub NA, Hunt BJ, Hughes GR. The management of thrombosis in the antiphospholipid-antibody syndrome. *N Engl J Med.* 1995; 332: 993-7.
  - 7 Miyakis S, Lockshin MD, Atsumi T, Branch DW, Brey RL, Cervera R, et al. International consensus statement on an update of the classification criteria for definite antiphospholipid syndrome (APS). *J Thromb Haemost.* 2006; 4: 295-306.
  - 8 Levine JS, Branch DW, Rauch J. The antiphospholipid syndrome. *N Engl J Med.* 2002; 346: 752-63.
  - 9 Provenzale JM, Ortel TL, Allen NB. Systemic thrombosis in patients with antiphospholipid antibodies: lesion distribution and imaging findings. *AJR Am J Roentgenol.* 1998 Feb; 170: 285-90.
  - 10 Alcazar-Ramirez JD, Fernández-Nebro A, Abarca M, Salgado F, De Haro-Liger M, Rodríguez-Andreu J, et al. Central vein thrombosis in the antiphospholipid syndrome. *Lupus.* 1997; 6: 549-51.
  - 11 Ozkan M, Eser B, Er O, Altuntas F, Coskun R, Topsakal R, et al. Antiphospholipid syndrome associated with malignant mesothelioma presenting with superior vena cava thrombosis: a case report. *Clin Appl Thromb Hemost.* 2004; 10: 393-6.
  - 12 Qanadli SD, El Hajjam M, Mignon F, de Kerviler E, Rocha P, Barré O, et al. Subacute and chronic benign superior vena cava obstructions: endovascular treatment with self-expanding metallic stents. *AJR Am J Roentgenol.* 1999; 173: 159-64.
  - 13 Doty JR, Flores JH, Doty DB. Superior vena cava obstruction: bypass using spiral vein graft. *Ann Thorac Surg.* 1999; 67: 1111-6.