

## ORIGINAL ARTICLE

# IgG Avidity Test for Ocular Toxoplasmosis Diagnosis at a Tertiary Center, Northeast of Iran

Elham Moghaddas<sup>1</sup>, Seyedeh Maryam Hosseini<sup>2</sup>, Karim Sharifi<sup>1</sup>, Abdolrahim Rezai<sup>3</sup>, Saman Soleimanpour<sup>4</sup>, Mohammad Mobin Miri Moghaddam<sup>5</sup>, Seyed Aliakbar Shamsian<sup>1\*</sup>

<sup>1</sup>Department of Parasitology and Mycology, Faculty of Medicine, <sup>2</sup>Eye Research Center, <sup>3</sup>Department of Immunology, Faculty of Medicine, <sup>4</sup>Microbiology and Virology Research Center, Antimicrobial Resistance Research Center, <sup>5</sup>Student Research Committee, Faculty of Medicine, Mashhad University of Medical Sciences, Mashhad, Iran

## ABSTRACT

**Background:** The diagnostic methods which are used for acute ocular toxoplasmosis are very important; if the treatment is delayed, it sometimes leads to loss of vision. Few studies have been performed to evaluate serological tests used in the diagnosis of acute ocular toxoplasmosis. **Objective:** To evaluate the immunoglobulin (Ig) M, G and IgG avidity tests for diagnosis of acute ocular toxoplasmosis in the northeast of Iran. **Methods:** A cross-sectional study was carried out from January 2014 to December 2016. After an ophthalmic examination was conducted by a retina specialist, 16 typical acute and 34 typical chronic ocular toxoplasmosis cases were included in this study. Information on clinical manifestations, age and occupation was recorded. Anti-*Toxoplasma* IgG, IgM and IgG avidity tests were administered on serum samples using the ELISA method. **Results:** Blurring of vision in all patients was the most clinical presentation. The IgG avidity test could diagnose all acute and recent cases. However, three false positive and one false negative result occurred using the IgM test by ELISA. The false negative result in all likelihood occurred because the patient was at the beginning stage of the infection. **Conclusion:** The result of this study showed that IgM is not a reliable marker of acute disease. Repetition of the serology tests was proposed in cases with clinical manifestations without detectable antibody titer after approximately two weeks. IgG avidity testing results coincided with clinical diagnosis and it could therefore considered to be a reliable method to differentiate between recently acquired and chronic ocular toxoplasmosis.

Received: 2018-02-11, Revised: 2019-05-21, Accepted: 2019-06-10.

**Citation:** Moghaddas E, Hosseini SM, Sharifi K, Rezai A, Soleimanpour S, Miri Moghaddam MM, Shamsian SA. IgG Avidity Test for Ocular Toxoplasmosis Diagnosis at a Tertiary Center, Northeast of Iran. *Iran J Immunol.* 2019; 16(3):258-264. doi: 10.22034/iji.2019.80277.

**Keywords:** ELISA, IgG Avidity Test, Ocular Toxoplasmosis

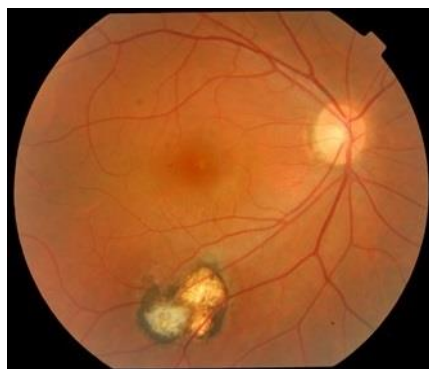
\*Corresponding author: Dr. Seyed Aliakbar Shamsian, Departments of Parasitology and Mycology, Faculty of Medicine, Mashhad University of Medical Sciences, Mashhad, Iran, e-mail: Shamsianaa@mums.ac.ir

## INTRODUCTION

*Toxoplasma gondii* (*T. gondii*) infects approximately one third of the world's human population (1). Ocular toxoplasmosis (OT) may be acquired congenitally or postnatally. Acquired toxoplasmosis occurs through the ingestion of contaminated vegetables or water, swallowing of oocytes after handling cat litter, or through consumption of uncooked, cured, dried or smoked meat (2). This protozoan parasite is responsible for up to 50% of posterior uveitis in the world. Twenty percent of uveitis is caused by *T. gondii* as reported by the largest ophthalmology center in the northeast of Iran (3). Different strains, pathogenicity and indistinctive genotypes of *T. gondii* in ocular form produce different immunoglobulin levels (4). Interpreting the positivity patterns of immunoglobulins G and M have some limitations especially regarding acquired or congenital ocular toxoplasmosis. The IgG avidity test, as a first FDA-approved method has been evaluated in numerous studies (5). Currently the IgG avidity test is used mostly for the differentiation of recent and past toxoplasmosis in pregnant women and it is used less for diagnosis of OT (6). Low IgG avidity (<40) is not considered specific for recently acquired OT, but its higher level (>40) confirms an old infection, but totally positive IgM with a low IgG avidity index is considered an acute case (usually defined as acquisition of infection in recent 6 months) and negative IgM with high IgG avidity index is considered a chronic disease. Positive IgM (due to the high half-life) with a high IgG avidity index shows a false positive of an acute disease (7). Also, Rheumatoid Factor (RF) can cause a false positive IgM (8). Eye specialists can diagnose reactivation (chronic) or recently (acute) OT except in atypical cases (9). In Iran the IgG avidity test is considered defective in terms of efficiency and reliability for the diagnosis of acute or chronic OT. The detection of IgG and IgM antibodies in patients with toxoplasmosis shows the presence of infection, but it does not determine the infection phase or the onset of toxoplasmosis (10). This is more significant in atypical presentation cases. The purpose of this study is to evaluate the immunoglobulin (Ig) M, G and IgG avidity for detection of acute ocular toxoplasmosis in northeast of Iran.

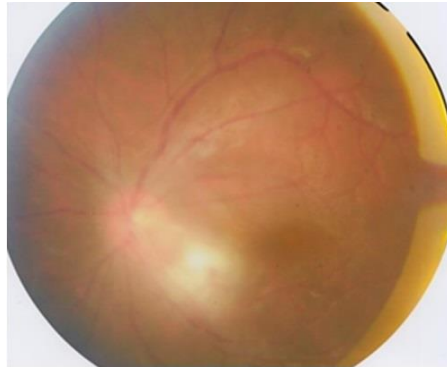
## MATERIALS AND METHODS

**Patient.** This cross-sectional study was performed at Khatam- al- Anbia Eye Hospital in the Mashhad University of Medical Sciences during January 2014 and December 2016.



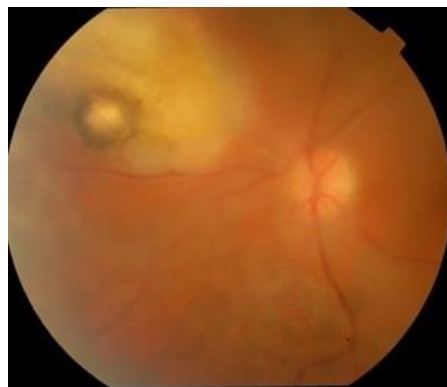**Figure 1.** Fundus photography of left eye discloses inactive pigmented toxoplasmosis scar.

In the present study, 50 typical or primary patients including 16 acute (Figure 1) and 34 chronic or recurrent (Figures 2 and 3) patients of ocular toxoplasmosis were included and two suspected cases were excluded after ophthalmological examinations.



**Figure 2. Active primary toxoplasmosis retinitis adjacent to optic nerve and macula (arrow) with hazy media due to vitritis.**

A positive diagnosis of OT was made following the confirmation of focal active creamy-white retinal inflammation (retinochoroiditis) adjacent to a chorioretinal scar. The presence of scar tissue indicates recurrent or chronic toxoplasmic retinochoroiditis which is typical OT. Typical acute or primary OT involves no scar, so the diagnosis was based on the clinical pattern of focal creamy-white retinitis which is associated with vitritis. After acquiring the written informed consents, 4 ml of peripheral blood was collected, centrifuged at 2,000 rpm in 5 min and serums were separated in a new tube and stored at  $-20^{\circ}\text{C}$  for serologic studies.



**Figure 3. Recurrent active retino-choroiditis adjacent to hyper-pigmented old toxoplasmosis scar.**

**Ethical Approval.** All procedures performed in studies involving human participants were in accordance with the ethical standards of the institutional and/or national

research committee and with the 1964 Helsinki declaration and its later amendments or comparable ethical standards, Ethical code: IR.MUMS.fm.REC.1394.544.

**ELISA.** IgG avidity status was determined using commercial anti-*T. gondii* assay ELISA for avidity determination (IgG) (Germany, EUROIMMUN, EI 2410-1). The avidity test was done according to Headmen's method (11) as follows: 100 µL of the patient's diluted sera were added to micro plates coated with *Toxoplasma* antigen. In the next step, concentrated (8M) urea solution was added to the antigen-antibody complex. After washing the excess antibody, labeled anti-IgG antibody was added to the test microplates. After incubation for 30 minutes and re-washing, a substrate solution was added. Finally, sulfuric acid was added as a stop solution. The optical density (OD) was measured at 450 nm against the differential wavelength of 600 nm. The avidity was measured by this formula: Avidity Index (%) = (OD of the sample treated with Urea – OD of the blank)/ (OD of the sample treated without Urea) ×100. An IgG avidity up to 40% indicates primary infection that has occurred for more than 3 months while lower than 40% shows a recent toxoplasmosis infection for less than three months. Also, IgM and IgG were detected according to the manufacturer's instructions (Germany, EUROIMMUN). They were considered positive greater than 11 IU / ml for IgG and higher than 1.1 IU / ml for IgM. IgG and IgM titers were performed for all patients including the acute and chronic ocular toxoplasmosis patients. The IgG avidity test was only performed for IgM positive cases.

## RESULTS

In total, 50 patients (16 typical acute and 34 typical chronic patients diagnosed on the basis of eye examinations and clinical manifestations) were enlisted in the current study. All results of IgG avidity tests were consistent with the diagnoses made by the ophthalmologist. Three patients were IgM positive while IgG avidity was observed to be >40 (we had three false positive cases). One case showed OT signs in clinical examination with negative serology (we had one false negative patient), she had a positive IgM titer after 3 weeks without any treatment. The OD of the acute ocular toxoplasmosis (16 patients) in ELISA system is shown in Figure 4.

**Table 1. Ocular manifestations at presentation in patients with ocular inflammation.**

Clinical manifestation	Acute	Chronic
Blurring of vision	12 (75%)	10 (29%)
Eye pain	1 (6.25%)	0
Floaters	2 (12.5%)	1 (3%)
Redness	1 (6.25%)	0

Blurring of vision (70%) (Table 1) was the most frequent clinical manifestation (Table 1). OT was observed mostly in the housekeepers (40%) (Table 2). Forty out of fifty (80%) OT patients were aged 20-40 years old with a mean age of 32.3 years old and 41 (82%) of them lived in urban areas.

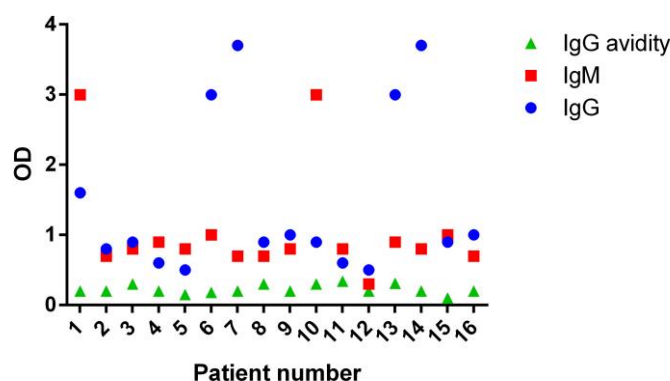


Figure 4. OD of the acute ocular toxoplasmosis of 16 patients in ELISA system.

47 (94%) patients had posterior uveitis and only 3 patients had panuveitis. 46 patients had unilateral involvement, besides 4 (8%) patients who had bilateral involvement.

Table 2. Ocular toxoplasmosis and occupations.

Occupation	Acute toxoplasmosis	Chronic toxoplasmosis	Total
housekeeper	8 (50%)	12 (35.3%)	20 (40%)
student	3 (18.7%)	4 (11.9%)	7 (14%)
Farmer	1 (6.3%)	2 (5.8%)	3 (6%)
self-employment	3 (18.7%)	14 (41.2%)	17 (34%)
employee	1 (6.3%)	2 (5.8%)	3 (6%)
<b>Total</b>	<b>16 (100%)</b>	<b>34 (100%)</b>	<b>50 (100%)</b>

## DISCUSSION

In this study, the IgG avidity test for diagnosis of ocular toxoplasmosis had a sensitivity of 100%. IgM and IgG ELISA tests may be needed to support the IgG avidity results. This test was performed on specific IgM positive samples and could determine the time of starting of toxoplasmosis (12). Anti- *T. gondii* IgM alone is not an accurate marker of acute infection, because IgM antibodies can remain for more than one year (12). Perhaps special strains caused different clinical features or made complicated cases. Unfortunately, very little is known about *T. gondii* genotyping. It is recommended to conduct a study regarding identification of *T. gondii* strains in ocular toxoplasmosis. We had three false positives that showed acute infection according to the IgM titer result. Results of IgG, IgM and IgG avidity tests coincided with each other in seventeen OT patients (IgG<sup>+</sup>IgM<sup>+</sup> with low IgG avidity) (13) while in another study, 103 out of 225 (45.8%) pregnant women showed IgG<sup>+</sup>, IgM<sup>+</sup> with high avidity (8). Among 93 (74.4%) serum samples from pregnant women which showed IgM<sup>+</sup> ELISA, 52 (55.9%) had high-avidity antibodies, which suggests that the infection was not acute and it did not require treatment (14). These findings highlight the value of IgG avidity testing for diagnosis of true acute toxoplasmosis. On the other hand, it recommends that IgG

avidity testing should be done along with IgM measurement in order to confirm acute toxoplasmosis (12). Frequently, ocular toxoplasmosis is diagnosed based in clinical presentations through ophthalmic examinations. Sometimes the clinical features cannot lead to a definitive diagnosis, therefore detection of increased *T. gondii* antibody titers in ocular fluids or blood serum can be used to confirm the diagnosis (15). For example, in the present study 2/50 cases were questionable but in the study of Kianersi *et al.* (2012), it was reported to be 8 out of 193 (16). Clinical diagnosis is introduced as the most sensitive (73%) way compared to antibody ratio (57%), PCR (26%), IgA (9%) and antibody-avidity (6%) (17). In this study, one patient showed a false negative result. This patient was diagnosed with an acute form based on eye examination without a positive IgM titer. According to the study by Garweg *et al.* these patients have probably been at the beginning stage of infection but specific antibody has not been produced yet (18). In this case, another IgM test was performed which was positive. 32 out of 117 (27.4%) patients were negative in all serological tests (IgM, IgG and IgG avidity), so negative serologic evidence is not a reliable for diagnosis of OT (13). In this study, blurring of vision was the most common complaint of patients similar to other studies (15,19). In this study, 80 percent of cases were aged 20-40 years old. Most of OT patients present before the age of 40 years old (20,21). It reports that age was a significant factor in the development of this disease (22). Similar to our study, OT was observed less in older people (23). Maybe a high consumption of non-pasteurized dairy products or lack of hygiene resulted in a high level of immunity against *T. gondii*. In general, OT was reported to be more prevalent in females (16,24). 20 out of 25 females who suffered from OT were housewives. It is possible that they did chores which might increase the possibility of protozoan transmission such as chopping raw meat, washing vegetables or changing cats' litter. Limitations regarding the IgG avidity method are firstly, reactivation of OT in patients cannot be detected with IgG avidity and secondly, a low IgG avidity does not always show a recent infection (12) but in this study, the results of the IgG avidity test were completely consistent with clinical diagnosis and acute ocular toxoplasmosis. In Conclusion, IgG avidity testing is a reliable method for the definitive diagnosis of acute OT. Also, it is possible to see the negative serology results in serum samples despite the clinical presentations of OT.

## ACKNOWLEDGEMENTS

This study was supported by a University research grant (940902) from the Mashhad University of Medical Sciences, for the support of a M.Sc. thesis.

## REFERENCES

1. Montoya J, Liesenfeld O. Toxoplasmosis. *Lancet*. 2004; 363:1965-76.
2. Jones JL, Muccioli C, Belfort JR, Holland GN, Roberts JM, Silveira C. Recently acquired *Toxoplasma gondii* infection, Brazil. *Emerg Infect Dis*. 2006; 12:582-7.
3. Hosseini SM, Moghaddas E, Sharifi K, Dadgar Moghaddam M, Shamsian SA. Assessment of Ocular Toxoplasmosis patients Reported at a Tertiary Center in the Northeast of Iran. *Int Ophthalmol*. 2018; 38:2527-2533.
4. Araujo FG, Slifer T. Different strains of *Toxoplasma gondii* induce different cytokine responses in CBA/Ca mice. *Infect Immun*. 2003; 71:4171-4174.

5. Maldonado YA, Read JS. Diagnosis, treatment, and prevention of congenital toxoplasmosis in the United States. *Pediatrics*. 2017; 139. pii: e20163860.
6. Fricker-Hidalgo H, Cimon B, Chemla C, Dardé M-L, Delhaes L, L'ollivier C, et al. *Toxoplasma* seroconversion with negative or transient immunoglobulin M in pregnant women: myth or reality? A French multicentre retrospective study. *J Clin Microbiol*. 2013; 51:2103-11.
7. Silveira C, Vallochi AL, da Silva UR, Muccioli C, Holland GN, Nussenblatt RB, et al. *Toxoplasma gondii* in the peripheral blood of patients with acute and chronic toxoplasmosis. *Br J Ophthalmol*. 2011; 95:396-400.
8. Naot Y, Barnett E, Remington J. Method for avoiding false-positive results occurring in immunoglobulin M enzyme-linked immunosorbent assays due to presence of both rheumatoid factor and antinuclear antibodies. *J Clin Microbiol*. 1981; 14:73-78.
9. Ozgonul C, Besirli CG. Recent developments in the diagnosis and treatment of ocular toxoplasmosis. *Ophthalmic Res*. 2017; 57:1-12.
10. Contreras M. IgG Avidity Test to Discriminate between Acute and Chronic Toxoplasmosis. *Am J Clin Microbiol Antimicrob*. 2018; 1:1012.
11. Joynson D, Payne R, Rawal B. Potential role of IgG avidity for diagnosing toxoplasmosis. *J Clin Pathol*. 1990; 43:1032-1033.
12. Rahbari AH, Keshavarz H, Shojaee S, Mohebbali M, Rezaeian M. IgG avidity ELISA test for diagnosis of acute toxoplasmosis in humans. *Korean J Parasitol*. 2012; 50:99-102.
13. Rahimi-Esboei B, Zarei M, Mohebbali M, Valian HK, Shojaee S, Mahmoudzadeh R, et al. Serologic Tests of IgG and IgM Antibodies and IgG Avidity for Diagnosis of Ocular Toxoplasmosis. *Korean J parasitol*. 2018; 56:147-152.
14. Liesenfeld O, Montoya JG, Kinney S, Press C, Remington JS. Effect of testing for IgG avidity in the diagnosis of *Toxoplasma gondii* infection in pregnant women: experience in a US reference laboratory. *J Infect Dis*. 2001; 183:1248-1253.
15. Park Y-H, Nam H-W. Clinical features and treatment of ocular toxoplasmosis. *Korean J Parasitol*. 2013; 51:393-9.
16. Kianersi F, Beni AN, Beni ZN. Clinical manifestation and prognosis of active ocular toxoplasmosis in Iran. *Internation ophthalmol*. 2012; 32:539-545.
17. Garweg JG, Jacquier P, Boehnke M. Early aqueous humor analysis in patients with human ocular toxoplasmosis. *J clin microbiol*. 2000; 38:996-1001.
18. Garweg J. Determinants of immunodiagnostic success in human ocular toxoplasmosis. *Parasit immunol*. 2005; 27:61-68.
19. Suresh S, Nor-Masniwati S, Nor-Idahriani MN, Wan-Hazabbah W-H, Zeehaida M, Zunaina E. Serological IgG avidity test for ocular toxoplasmosis. *Clin ophthalmol*. 2012; 6:147-150.
20. Dodds EM, Holland GN, Stanford MR, Yu F, Siu WO, Shah KH, et al. Intraocular inflammation associated with ocular toxoplasmosis: relationships at initial examination. *Am J Ophthalmol*. 2008; 146:856-865.
21. Bosch-Driessen LE, Berendschot TT, Ongkosuwito JV, Rothova A. Ocular toxoplasmosis: clinical features and prognosis of 154 patients. *Ophthalmol*. 2002; 109:869-878.
22. Holland GN. Ocular toxoplasmosis: the influence of patient age. *Mem Inst Oswaldo Cruz*. 2009; 104:351-357.
23. Marques J, Da Silva D, Correia N, Velásquez G, Da Silva R, Langoni H, et al. Prevalence and risk factors for human toxoplasmosis in a rural community. *J Venom Anim Toxins Incl Trop Dis*. 2008; 14:673-684.
24. Aleixo ALQdC, Benchimol EI, Neves EdS, Silva CSP, Coura LC, Amendoeira MRR. Frequency of lesions suggestive of ocular toxoplasmosis among a rural population in the State of Rio de Janeiro. *Rev Soc Bras Med Trop*. 2009; 42:165-169.