



Case Report of China/Tianjin's First Novel Coronavirus Variant Omicron

Haibai Sun^{1#}, Hongjie Li[#], Shuping Huang¹, Lixia Shi¹, Zhiheng Xing¹, Jun Shen^{1*}

¹Tianjin Institute of Respiratory Diseases, Tianjin Haihe Hospital, 890 Jingu Road, Shuanggang Town, Jinnan District, Tianjin, China

#Authors contributed equally.

ABSTRACT

COVID-19 is a new acute respiratory infectious disease caused by a novel Coronavirus (2019-COV-2) infection. On November 26, 2021, the World Health Organization announced a new 2019-COV-2 variant strain Omicron (B.1.1.529). Omicron's emergence added further uncertainty to the outbreak. Here we report the first case infected with Omicron in China, a 17-year-old female student. In this paper, the clinical symptoms, laboratory and imaging examinations and treatment of the first Omicron-infected patient in China were analyzed. This report might provide a reference for the diagnosis and treatment of patients infected with Omicron strain across the world. The novel Coronavirus antibody tests were performed on the day of admission: IgM level was normal, novel Coronavirus antibody IgG was 132.666s /CO and IgG was 148.47s /CO on the 7th day of admission. IgG showed an increasing trend, which is consistent with the results of multiple novel Coronavirus non-Omicron strain infections.

Keywords: COVID-19, Laboratory examination, Omicron Variant, SARS-CoV-2

*Corresponding author:

Jun Shen,
Tianjin Haihe Hospital, 890
Jingu Road, Shuanggang Town,
Jinnan District, Tianjin, 300350,
China
Email: oij36985@126.com

Cite this article as:

Sun H, Li H, Huang S, Shi L,
Xing Z, Shen J. Case Report
of China/Tianjin's First Novel
Coronavirus Variant Omicron. *Iran
J Immunol.* 2022; 19(1):115-120,
doi: 10.22034/IJI.2022.94050.2278.

Received: 2021-12-22

Revised: 2021-12-25

Accepted: 2021-12-26

CASE INFORMATION AND DEVELOPMENT

General Information

The patient is a 17-year-old female student from Poland, who previously lived in Warsaw, Poland, and on December 9, 2021, entered from Tianjin Binhai International Airport. The results of the coronavirus nucleic acid tests (nose/throat) performed by the customs lab were positive. Tianjin Center for Disease Control and Prevention (CDC) examined the respiratory tract specimens for respiratory virus genome sequencing and sequence

analysis. China CDC further confirmed this patient was infected with the novel Coronavirus variant Omicron. The patient reported that she did not feel cold, and presented no fever, nasal congestion, runny nose, cough, sputum, chest tightness, suffocation, loss of taste and smell, abdominal pain, diarrhea, fatigue, or muscle pain. The patient was transferred to our hospital for further isolation and treatment. Since the onset of the disease, the patient had a decent night's rest, a positive mindset, and a healthy nutrition, normal bowel movements, and no significant weight loss either. She had previously been in decent mental shape, with

no history of hypertension, coronary heart disease, infection, surgery, blood transfusion, drug or food allergy, and she kept normal menstruation. The patient received two doses of COVID-19 vaccine (Pfizer) on September 6, 2021 and September 27, 2021. The patient's temperature was 37.3°C at admission, and the physical examination was normal.

Auxiliary Examination

Novel Coronavirus nucleic acid test positive (nose/pharynx) in the Customs Lab on December 9, 2021, (PCR test using a kit from Liferiver: 33.64/31.75/31.98; from Daan: 31.87/29.96).

Lab Examination

The blood routine results on Day 1 (Dec 9th) and 6 (Dec 15th) upon admission have been included in Table 1. To note, the neutrophil percentage was slightly high while the lymphocyte percentage was low on Day

1. On Day 6, the blood routine examination showed that ratios of monocytes, basophils, and CD4+T cells increased slightly while the lymphocyte percentage decreased (Table 2). All the nucleic acid test results have been included in Table 3, showing that the test results turned negative (nasal/pharynx) on December 16th and 20th. The changes in the virus antibody IgG and IgM in the patient have been displayed in Table 4. The test results for C-reactive protein were both lower than 0.200 mg/L, as sampled on Days 1 and 6. The coagulation conditions of the patient on Day 1 have been as shown in Table 5. On Day 6, the D-dimer was 0.16 mg/L and coagulation parameters were in a normal range. On the other hand, tests on Day 6 showed that routine urine pH decreased to 5.0 while liver and kidney function, electrolytes, glucose, and invasive blood transfusion were normal.

Imageological Examination

Chest CT results have shown subpleural

Table 1. Blood routine results during hospitalization

Test items	Dec 9th	Dec 15th	Unit	Normal range
White blood cell count	9.75	6.78	*10 ⁹ /L	4.10-11.10
Neutrophil percentage	78.6%	57.4%	*10 ⁹ /L	37-77%
Neutrophil count	7.67	3.89		1.80-8.30
Lymphocyte count	1.42	1.88	*10 ⁹ /L	1.20-3.80
Lymphocyte percentage	14.6%	27.7%		17-54%
Monocyte count	0.59	0.86	*10 ⁹ /L	0.14-0.74
Monocyte percentage	6.1%	12.7%		2-11%
Eosnophils count	0.03	0.07	*10 ⁹ /L	0.00-0.68
Eosnophils Percentage	0.3%	1%		0-9%
Basophilic granulocyte count	0.04	0.08	*10 ⁹ /L	0.00-0.07
Basophilic granulocyte percentage	0.4%	1.2%		0-1%
Red blood cell count	4.44	4.35	*10 ¹² /L	4.10-5.30
Haematocrit	0.39	0.378		0.360-0.470
Hemoglobin	132	127	g/L	114-154
Mean corpuscular volume	87.8	86.9	fL	82.00-100.00
Mean corpuscular hemoglobin	29.7	29.2	Pg	25.0-34.0
Mean corpuscular-hemoglobin concentration	338	336	g/L	310-355
Red blood cell volume distribution width	41.9	40.7	fL	37.0-54.0
Platlet	291	246	*10 ⁹ /L	150-407
Mean platelet volume	10.1	9.9	fL	9.4-12.5
Platlet volume distribution width	12.2	11.5	fL	9.0-17.0
Platlet hematocrit	0.3	0.24	%	0.108-0.270
Large-scale platlet percentage	30%	20%		10-40%

Table 2. T cell subset on Day 7

Test items	Results	Normal range
LYM%	23.63	27.90-37.30%
LYM	2095.83	1752.00-2708.00/ul
TLYM%	82.17	62.60-76.80%
TLYM	1722.08	1185.00-1901.00/ul
CD8+T%	30	19.20-33.60%
CD4+T%	47.47	30.00-46.00%
CD4+T	994.82	561-1137.00/ul
CD8+T	628.75	404.00-754.00/ul
CD4+/CD8+	1.58	0.89-2.01

Table 3. Nucleic acid testing results

2021/12/9	Throat swab	Positive
	Nose swab	Positive
2021/12/16	Throat swab	Negative
2021/12/20	Throat swab	Negative
	Nose swab	Negative

Table 4. The antibody IgG and IgM levels during hospitalization

	IgG (S/CO)	IgM (S/CO)
Dec 9th	132.666	0.347
Dec 15th	148.47	0.318
Normal range	0.000-1.000	0.000-1.000

Table 5. The coagulation functions during hospitalization

	Prothrombin time(sec)	Thrombin time(sec)	International standardized ratio of thrombin	Fibrinogen (g/L)	Activated partial thromboplastin time(sec)	D-dimer (mg/L)
Results	10.5	17.1	0.91	2.29	28.6	0.24
Normal range	10.0-15.0	16.0-26.0	0.8-1.5	2.00-4.00	24.0-40.0	0-0.55

nodules in the upper lobe of the left lung, indicating intrapulmonary lymph nodes (Figure 1) but no obvious imaging findings of viral pneumonia (Figure 2). Bilateral lower extremity arterial ultrasonography showed no obvious abnormality, and bilateral lower extremity deep vein ultrasonography showed no obvious thrombosis (Figure 3). Combined with the epidemiological history, clinical manifestations, and chest imaging, the preliminary diagnosis was as follows: imported novel Coronavirus infection

(asymptomatic infection). On Day 6, the left upper lobe apex posterior segment showed cable shadow, adjacent pleura displayed the trend of thickening and adhered, the left lung oblique fissure and the left upper lobe subpleural nodular shadow was shown, suggesting intrapulmonary lymph nodes.

TREATMENT

Traditional Chinese medicine consultation

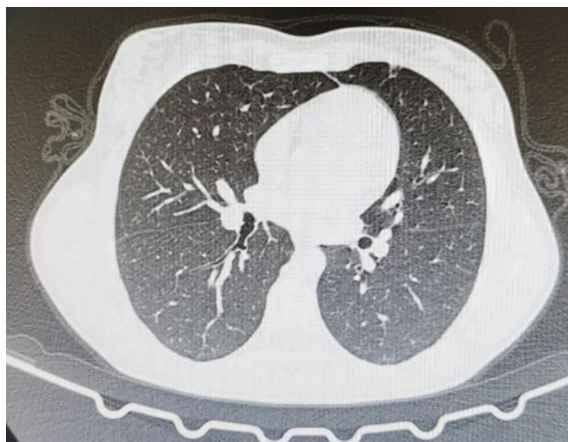


Figure 1. Chest spiral CT for the patient on Dec 9th.

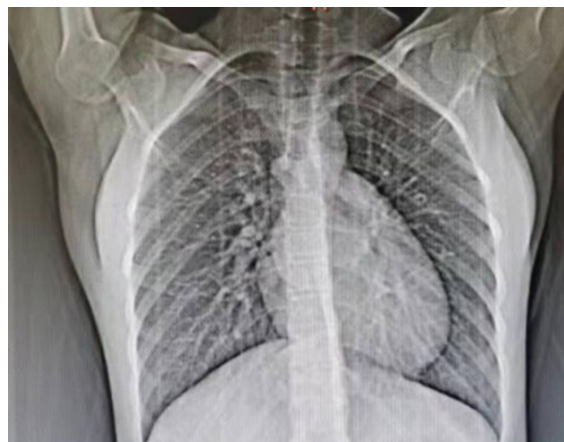


Figure 2. Front view of chest CT for the patient on Dec 9th.

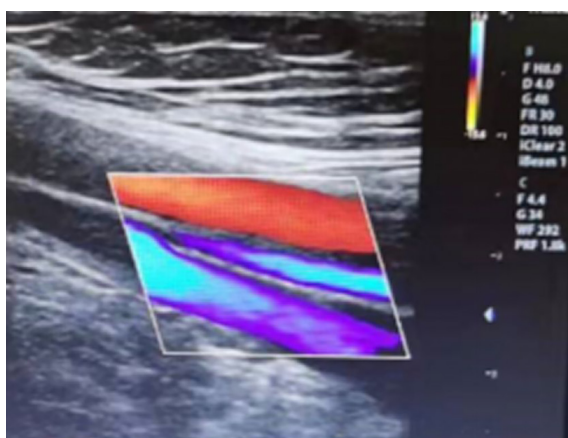


Figure 3. Color Doppler ultrasound for lower limb vascular for the patient on Dec 9th.

considered the patient's wet temperature disease, which belongs to the wet toxin stagnation lung syndrome. The recommended treatment was to alleviate the lung toxin, reduce humidity, and clear heat. The prescription was as follows: ephedra 3g, fried almond 8g, raw gypsum 15g, Coix seed 15g, bran fried *Atractylodes* 5g, patchouli 6g, Knotweed *cuspidata* 10g, *Verbena* 15g, *Asparagus* 15g, *Semen Lepidii* 8g, *exocarpium* 8g, licorice 5g. Decocted in water, 3 times/day, 1 dose per day. On Day 6 after admission, the patient's temperature was normal and her condition was generally fair and stable.

DISCUSSION

Sars-cov-2 emerged as a new human-to-human virus, triggering a pandemic that has

seriously threatened global human health in the past two years (1). On 26 of November 2021, the World Health Organization announced a new SARS-COV-2 variant, Omicron (B.1.1.529) (2). This is another severe novel Coronavirus mutation following the Delta variant. Emma Hodcroft, a virologist at the University of Bern, has said that Omicron was so different from the millions of SARS-COV-2 genomes that have been shared publicly, so that it was difficult to determine their parental generation. At the same time, researchers in Botswana and South Africa found that Omicron carries a large number of mutations in its spike protein that affect the ability of antibodies to recognize the virus and prevent infection (3). The Omicron variant carries 32 abnormal mutations in the spike protein, which is the main antigenic target, compared with only 5 mutations in the destructive Delta variant, which poses a high potential global risk and has spread internationally (4).

This case was the first Omicron imported in China. After admission, she was in fine health overall, with no abnormality in physical examination. The total number of white blood cells was normal, the percentage of neutrophils only slightly increased, and the percentage of lymphocytes slightly decreased in laboratory examination, which was consistent with other COVID-19 studies (5). In addition, it is widely believed that IgM is the first line of defense in case of viral infection, while

IgG production lags behind IgM and provides long-term immunity and memory. Xu et al. observed that IgM levels were relatively low in the first week of COVID-19 patients, and IgG levels were higher than IgM (6). Novel Coronavirus antibody tests were performed on the day of admission: IgM level was normal, novel Coronavirus antibody IgG was 132.666s /CO and IgG was 148.47s /CO on the 7th day of admission (Table 4). IgG showed an increasing trend, which is consistent with the results of multiple novel Coronavirus non-Omicron strain infections (7-9). This may be related to the fact that COVID-19 patients are asymptomatic in the early stages of infection. Clinicians recorded the day the patient developed symptoms such as fatigue, fever, cough, or diarrhea as the onset day. However, due to asymptomatic infection, the date of onset may be later than the date of infection, which explains why IgG levels were higher in the first week after the onset day. Han H et al.'s study found that compared with a healthy control population, the coagulation function of COVID-19 patients seems to be significantly disordered, D-dimer values in severe groups significantly increased, and D-dimer can be a special predictor of disease progression (10). In this case study, D-dimer and the rest coagulation results of the patient were within the normal range, bilateral lower limb arterial ultrasonography showed no obvious abnormalities, and bilateral lower limb deep vein ultrasonography showed no obvious thrombosis. C-reactive protein did not elevate, and the Omicron-infected patient showed no obvious clinical symptoms compared with those with severe COVID-19, while laboratory tests were normal.

To sum up, the first imported patient infected with Omicron showed no obvious clinical symptoms during admission, and laboratory examination has no obvious abnormalities. Asymptomatic patients, if treated with traditional Chinese medicine during hospitalization, accompanied by first-grade nursing, can smoothly recover. Although the patient infected with Omicron

showed only mild symptoms, the strain is highly contagious with strong pathogenicity. It is of significance to isolate the patients and prevent the potential of its spread.

Funding: Number TJWJ2021MS035 Study on the expression of IP-10 by interferon γ in COVID-19 patients based on JAK-Stat signaling pathway

ETHIC APPROVAL

This study is approved by relevant Ethics Committee. This study is also obtained the signed informed consent from patient.

Conflict of Interest: None declared.

REFERENCES

1. Wu Z, McGoogan JM. Characteristics of and important lessons from the coronavirus disease 2019 (COVID-19) outbreak in China: summary of a report of 72314 cases from the Chinese center for disease control and prevention. *JAMA*. (2020) 323:1239–42. doi: 10.1001/jama.2020.2648.)
2. Scott L, Hsiao NY, Moyo S, Singh L, Tegally H, Dor G, Maes P, Pybus OG, Kraemer MUG, Semenova E, Bhatt S, Flaxman S, Faria NR, de Oliveira T. Track Omicron's spread with molecular data. *Science*. 2021 Dec 17;374(6574):1454-1455. doi: 10.1126/science.abn4543. Epub 2021 Dec 9. PMID: 34882437.
3. Callaway E. Omicron likely to weaken COVID vaccine protection. *Nature*. 2021 Dec;600(7889):367-368. doi: 10.1038/d41586-021-03672-3. PMID: 34880488.
4. Chen J, Wang R, Gilby NB, Wei GW. Omicron (B.1.1.529): Infectivity, vaccine breakthrough, and antibody resistance. *ArXiv [Preprint]*. 2021 Dec 1;arXiv:2112.01318v1. PMID: 34873578; PMCID: PMC8647651.
5. He R, Lu Z, Zhang L, Fan T, Xiong R, Shen X, Feng H, Meng H, Lin W, Jiang W, Geng Q. The clinical course and its correlated immune status in COVID-19 pneumonia. *J Clin Virol*. 2020 Jun;127:104361. doi: 10.1016/j.jcv.2020.104361. Epub 2020 Apr 12. PMID: 32344320; PMCID: PMC7152870.
6. Xu, X. et al. Seroprevalence of immunoglobulin

- M and G antibodies against SARS-CoV-2 in China. *Nat. Med.* 26, 1193–1195 (2020).
7. Long, Q. X. et al. Clinical and immunological assessment of asymptomatic SARS-CoV-2 infections. *Nat. Med.* 26, 1200–1204 (2020).
 8. Wiersinga, W. J., Rhodes, A., Cheng, A. C., Peacock, S. J. & Prescott, H. C. Pathophysiology, transmission, diagnosis, and treatment of coronavirus disease 2019 (COVID-19): a review. *J. Am. Med. Assoc.* 324, 782–793 (2020). [PubMed]
 9. Li K, Huang B, Wu M, Zhong A, Li L, Cai Y, Wang Z, Wu L, Zhu M, Li J, Wang Z, Wu W, Li W, Bosco B, Gan Z, Qiao Q, Wu J, Wang Q, Wang S, Xia X. Dynamic changes in anti-SARS-CoV-2 antibodies during SARS-CoV-2 infection and recovery from COVID-19. *Nat Commun.* 2020 Nov 27;11(1):6044. doi: 10.1038/s41467-020-19943-y. PMID: 33247152; PMCID: PMC7699636.
 10. Han H, Yang L, Liu R, Liu F, Wu KL, Li J, Liu XH, Zhu CL. Prominent changes in blood coagulation of patients with SARS-CoV-2 infection. *Clin Chem Lab Med.* 2020 Jun 25;58(7):1116-1120. doi: 10.1515/cclm-2020-0188. PMID: 32172226.